

Original Article

Robot-assisted Thyroidectomy: Early Experience

Heon Soo Park MD PhD¹, Jong Chul Hong MD PhD^{•1}

Abstract

Background: The numbers of thyroid surgeries have been increasing recently. Robot-assisted thyroidectomy allows for a better cosmetic outcome in comparison with conventional open thyroidectomy.

Methods: We performed two robot-assisted endoscopic thyroidectomies by a gasless unilateral axillo-breast approach using the da Vinci surgical robot system.

Results: We performed right thyroid lobectomies in both patients. The pathologic reports were: micropapillary carcinoma without extracapsular invasion in patient 1 and a benign cyst in patient 2. The operation times were 165 minutes in patient 1 and 110 minutes in patient 2. No postoperative complications occurred.

Conclusion: Regarding our early experience, robotic thyroidectomy using the gasless axillo-breast approach is a safe, feasible, and cosmetically good procedure.

Keywords: Endoscopy, robot, thyroidectomy

Cite the article as: Park HS, Hong JC. Robot-assisted Thyroidectomy: Early Experience. *Arch Iran Med.* 2012; **15**(8): 488 – 490.

Introduction

Thyroid cancer is the most common endocrine malignancy, which is increasing worldwide. Among these, papillary cancers account for approximately 70%. The numbers of thyroid surgeries have been increasing recently. Young women with thyroid nodules are not only interested in disease management, but also cosmetic results. Traditional open thyroidectomy provides direct exposure with which to perform safe, rapid surgery with minimal mortality and almost no morbidity.¹ The incision line is only 4–5 cm, so most scars are invisible after one postoperative year. However, sometimes a hypertrophic scar develops which causes major cosmetic problems, particularly for young women.

For this reason various endoscopic thyroidectomy techniques have been developed. In 1997, Huscher first performed endoscopic thyroidectomy via a cervical approach.² Recently various endoscopic thyroid techniques or approaches have been described. The limitations of endoscopic thyroidectomy techniques include limited visualization of the surgical field due to the use of two-dimensional (2-D) representation and limited manipulation due to the use of nonflexible endoscope instruments.³ Recently the da Vinci surgical robot system (Intuitive Surgical, Sunnyvale, CA, USA) has been used in thyroid surgery to overcome the limitations of endoscopic surgery. Use of the dual channel endoscope, the da Vinci surgical robot system provides a three-dimensional (3-D) magnified surgical field. It also provides tremor-free handling, fine-motion scaling and a better range of motion in deep and

narrow spaces.

In this study, we report on our early experiences to evaluate the usefulness of robotic thyroidectomy in two patients.

Materials and Methods

Patients

We performed two robot-assisted endoscopic thyroidectomies by a gasless unilateral axillo-breast approach using the da Vinci surgical robot system at Dong-A University Hospital, Busan, Korea between June 2010 and July 2010. The operations were performed by a thyroid surgical team (HS Park & JC Hong) under general anesthesia.

Preoperative patient workup consisted of physical examination, ultrasonography, fine-needle aspiration cytology, and computed tomography. The fine-needle aspiration cytology proved papillary carcinoma in one patient and a benign cystic nodule in the other. The papillary carcinoma patient was a 44-year-old female (patient 1) and the cystic nodule patient was a 45-year-old female (patient 2). All nodules were located in the right thyroid gland. The computed tomographic image showed a 0.7 cm sized calcified nodule with no extrathyroidal extension and no lymph node metastasis in patient 1 (Figure 1A). In patient 2, the computed tomographic image showed a 3 × 3 cm sized homogenous cystic nodule in the right thyroid gland (Figure 1B). Preoperative laryngoscopic examination revealed normal vocal cord mobility in both patients. Informed consent was obtained from both patients for robotic thyroidectomy and for the possibility of conversion to conventional open thyroidectomy.

Surgical technique

The operative procedure included flap elevation, docking, and console stages. The patient was placed in the supine position with one arm extended over a small shoulder roll. For the axillo-breast

Authors' affiliation: ¹Department of Otorhinolaryngology, Head and Neck Surgery, Dong-A University College of Medicine, Busan, Korea.

•Corresponding author and reprints: Jong Chul Hong MD PhD, Department of Otolaryngology, Head and Neck Surgery, Dong-A University College of Medicine, 3-1 Dongdaeshin-Dong, Seo-Gu, Busan, 602-715, Korea.

Tel: +82-51-240-5428, Fax: +82-51-253-0712, E-mail: santa@dau.ac.kr

Accepted for publication: 18 January 2012

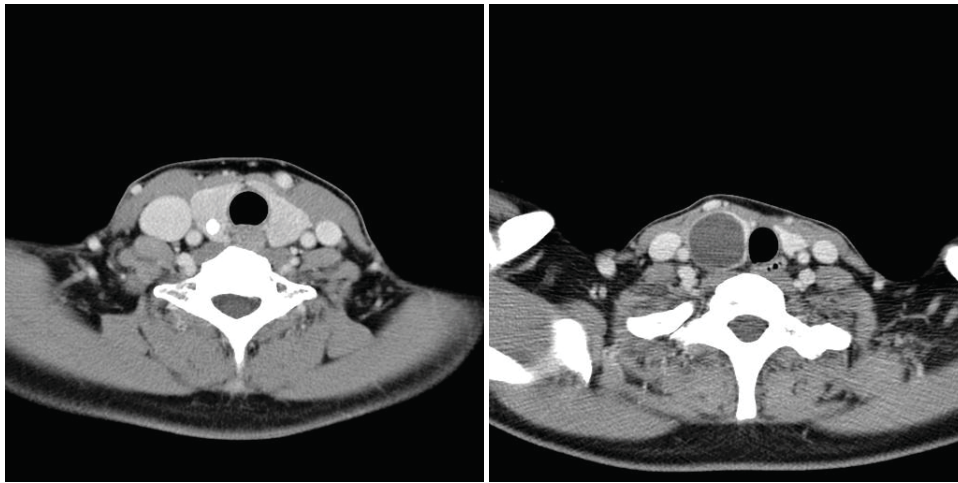

Figure 1. **A)** Computed tomographic image shows a 0.7 cm sized calcified nodule with no extrathyroidal extension and no lymph node metastasis in patient 1. **B)** In patient 2, the computed tomographic image shows a 3 × 3 cm-sized homogenous cystic nodule in the right thyroid gland.

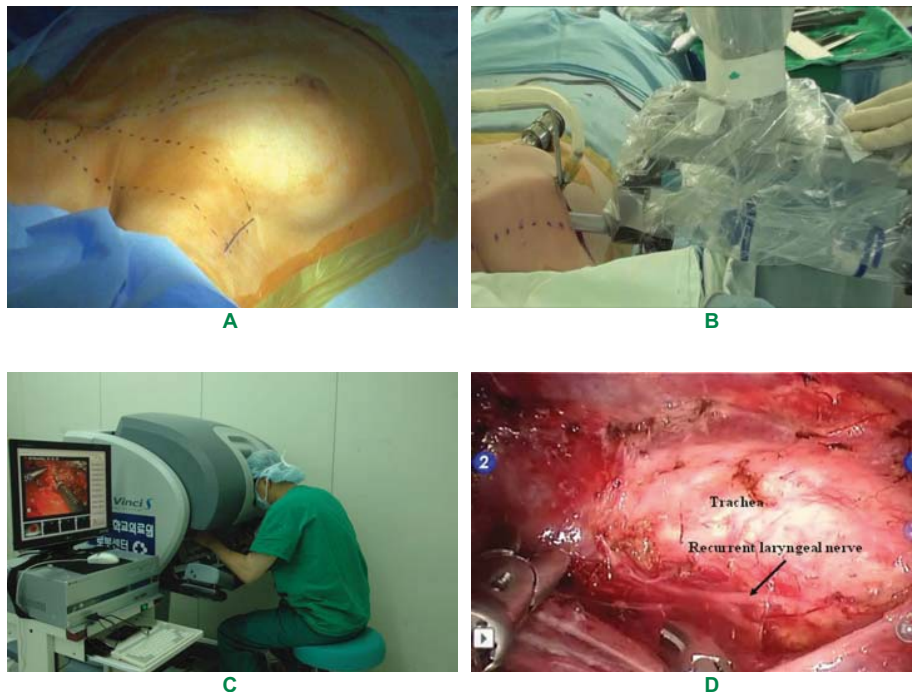


Figure 2. Robotic thyroidectomy **A)** The patient was positioned in the supine position. For the axillo-breast approach, a 6–8 cm skin incision was made in the axilla and an 0.8 cm skin incision on the ipsilateral circumareolar margin. **B)** Docking stage. The robotic arms are inserted through the axillary and circumareolar incisions. **C)** After the docking stage, the console stage begins. **D)** Following completion of the right thyroid lobectomy. The right recurrent laryngeal nerve and intact trachea are visualized.

approach, a 6–8 cm skin incision was made in the axilla and a 0.8 cm skin incision was made on the ipsilateral circumareolar margin (Figure 2A). Dissection was performed under direct visualization using electrocautery. After exposure of the sternocleidomastoid muscle, the sternal head and clavicular head were separated. The strap muscles (sternohyoid and sternothyroid muscles) were visualized; we carefully dissected underneath the strap muscles. After exposure of the thyroid gland, we inserted an external retractor to maintain working space without CO₂ gas insufflation. Through the axillary incision, three robotic arms (an endoscope, a dissector, and a Harmonic scalpel) were inserted. A fourth arm (prograsp forcep) was inserted through the ipsilateral circumareolar incision. This

was the docking stage (Figure 2B).

Following the docking stage, the console stage began (Figure 2C). During the thyroid dissection, the trachea was initially identified after which dissection was begun from the inferior to the superior pole. Parathyroid glands and recurrent laryngeal nerve were preserved. The ipsilateral thyroid gland was retracted medially and the isthmus divided. Thus, the thyroid lobectomy was completed (Figure 2D). The specimen was removed via the axillary incision and a closed suction drain inserted near the axillary incision, followed by skin closure.

Results

We performed right thyroid lobectomies in both patients. The pathologic reports were micropapillary carcinoma without extracapsular invasion in patient 1 and benign cyst in patient 2. Surgical times were 165 minutes in patient 1 and 110 minutes in patient 2. The operation time was divided into the flap elevation time, docking, and console stages. In patient 1, the flap elevation time was 60 minutes, docking stage was 15 minutes, and console stage was 90 minutes. In patient 2, the flap elevation time was 40 minutes, docking stage was 10 minutes, and console stage was 60 minutes. No vocal cord paralysis was observed on postoperative laryngoscopic examination. There was no occurrence of any postoperative hemorrhage, hypocalcemia or voice changes. Patients complained of mild anterior chest discomfort and pain, which was controlled with oral analgesics. Both patients were discharged on postoperative day five. In patient 1, no recurrence or distant metastasis was observed at the eight-month follow-up. Both patients expressed satisfaction with the surgical results and lack of an anterior neck scar.

Discussion

Although we performed robotic thyroidectomy in only two cases, the surgical outcomes were satisfactory. Many surgeons have reported the outcomes of robotic thyroidectomy in Korea.^{1,3,4} In Korea, due to improved economic status, patients are interested in not only disease cure but also quality of life, particularly with regards to cosmetic problems.

In young women, thyroid cancer is the most prevalent cancer in Korea. Therefore numerous techniques of minimal invasive endoscopic thyroidectomy have been developed. Since the da Vinci surgical robot system was introduced several years ago in Korea, robotic surgeries have been incorporated into the fields of gynecology, cardiovascular surgery, otolaryngology, and pediatric surgery.⁵

Robotic thyroidectomy has many advantages. It provides an excellent surgical view with 3-D magnification and seven degrees of freedom, scaled and tremor-filtered movement, and a multi-articulated endowrist.^{1,6} These enable surgeons to access deep, narrow spaces for complete cervical lymph node dissection and are likely to increase the facility of preserving the recurrent laryngeal nerve and parathyroid glands.^{1,4} No anterior neck scar occurs.

However, there are some disadvantages in robotic thyroidectomy. It is more invasive because of the wide dissection that is necessary, and it is more time consuming than conventional open thyroidectomy. Because the National Health Insurance in Korea does not cover the cost of robotic surgery, it is more expensive than open thyroidectomy. Other disadvantages are lack of both tactile sensation and tensile feedback to the surgeon. Therefore, robotic arms should not be moved out of surgical view because the force of the robotic arm is powerful and the surgeon cannot detect tissue damage caused by the robotic arm if moved out of view.⁴

In recent reports, the results of robotic thyroidectomy are similar to conventional open thyroidectomy or endoscopic thyroidectomy. According to Tae et al., there has been one case of transient vocal cord paralysis and two cases of transient hypoparathyroidism. The cosmetic satisfaction was superior to open thyroidectomy.¹ Lee et al. have reported clinical outcomes of robotic thyroidectomy performed on more than 1000 patients with thyroid carcinoma. There were 10 (1%) major and 274 (26.3%) minor complications. The

most common complication was transient hypocalcemia. Major complications included vocal cord paralysis, hematoma that resulted in a second surgery, and tracheal injury.³

In our cases no major or minor complications have been noted. If we perform more robotic thyroidectomies, the chances of complications increase. The operation time is significantly longer than open thyroidectomy. The mean operation time has been reported at 179 minutes according to Tae et al. and 132 minutes in a study by Lee et al.^{1,3} In our cases, surgical times were 165 and 110 minutes. We performed only lobectomies, of which these times were similar to other studies. According to our limited experience, more time was spent in total thyroidectomy with central lymph node dissection. Previous large multicenter series have shown that the learning curve for robotic thyroidectomy was greater than 40 cases.⁷ More experience in robotic surgery is needed to overcome this learning curve.

All thyroid surgeries are not indications for robotic thyroidectomy. The inclusion criteria in this study were similar to Lee et al.^{3,4} 1) differentiated thyroid carcinoma with tumor size < 2 cm, 2) benign tumor with tumor size < 5 cm, and 3) absence of definite extrathyroidal invasion, tracheoesophageal invasion, vocal cord paralysis, distant metastasis, and multiple lateral lymph node metastasis. In 2010, Kang et al. reported on robot-assisted modified radical neck dissection in patients with lateral neck node metastasis. They have reported no major complications and recurrences.⁶ However, since the experience of robotic thyroidectomy is less than ten years worldwide, oncologic outcomes are not easily determined compared to open thyroidectomy.

In conclusion, regarding our early experiences, robotic thyroidectomy using the gasless axillo-breast approach is a safe, feasible, and cosmetically good procedure. The robotic thyroidectomy will most likely become a more popular technique worldwide.

Conflict of Interest: None

Acknowledgments

This study was supported by research funds from Dong-A University.

References

1. Tae K, Ji YB, Jeong JH, Lee SH, Jeong MA, Park CW. Robotic thyroidectomy by a gasless unilateral axillo-breast or axillary approach: our early experiences. *Surg Endosc.* 2011; **25**: 221 – 228.
2. Huscher CS, Chiodini S, Napolitano C, Recher A. Endoscopic right lobectomy. *Surg Endosc.* 1997; **11**: 877.
3. Lee J, Yun JH, Nam KH, Choi UJ, Chung WY, Soh EY. Perioperative clinical outcomes after robotic thyroidectomy for thyroid carcinoma: a multicenter study. *Surg Endosc.* 2011; **25**: 906 – 912.
4. Lee J, Lee JH, Nah KY, Soh EY, Chung WY. Comparison of endoscopic and robotic thyroidectomy. *Ann Surg Oncol.* 2011; **18**: 1439 – 1446.
5. Landry CS, Grubbs EG, Stephen Morris G, Turner NS, Christopher Holsinger F, Lee JE, et al. Robot assisted transaxillary surgery (RATS) for the removal of thyroid and parathyroid glands. *Surgery.* 2011; **149**: 549 – 555.
6. Kang SW, Lee SH, Ryu HR, Lee KY, Jeong JJ, Nam KH, et al. Initial experience with robot-assisted modified radical neck dissection for the management of thyroid carcinoma with lateral neck node metastasis. *Surgery.* 2010; **148**: 1214 – 1221.
7. Lee J, Yun JH, Nam KH, Soh EY, Chung WY. The learning curve for robotic thyroidectomy: a multicenter study. *Ann Surg Oncol.* 2011; **18**: 226 – 232.